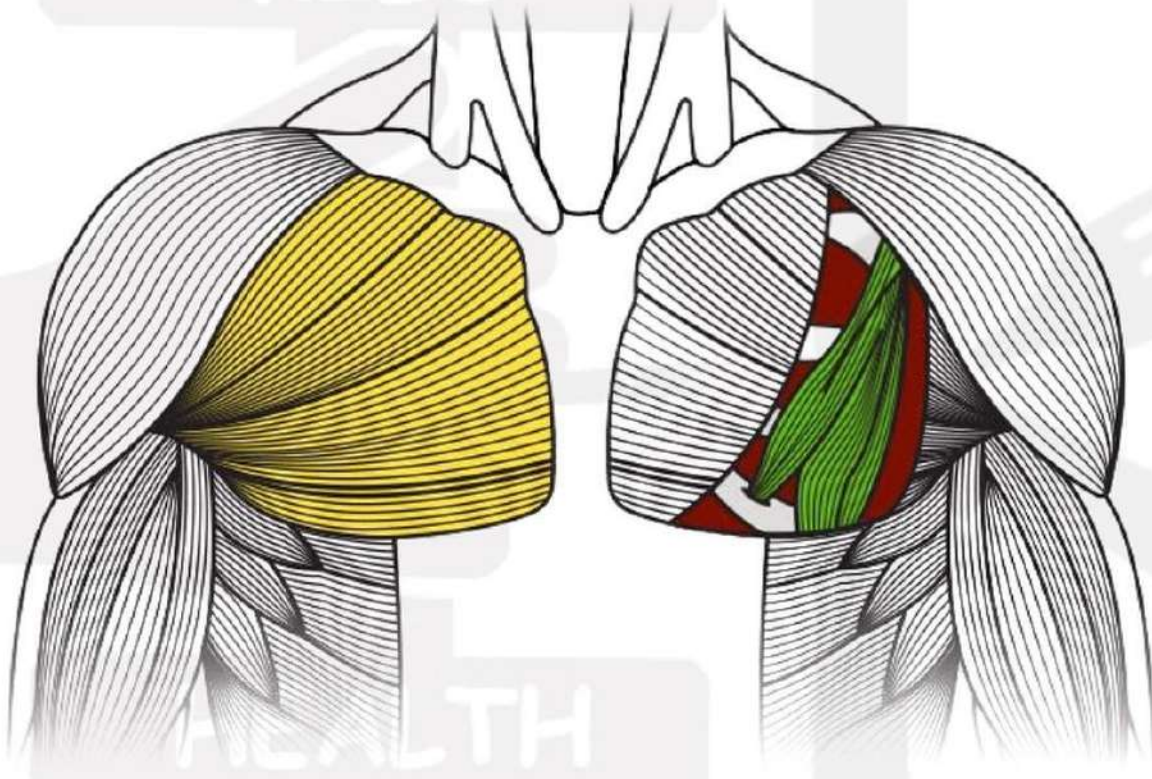


# ANATOMY OF THE CHEST

 @healthbykilo



## PECTORALIS MAJOR

Consists of sternal (lower) head and clavicular (upper) head.

## PECTORALIS MINOR

Helps move the scapula.

LIKE | COMMENT | SHARE

SAVE FOR  
LATER

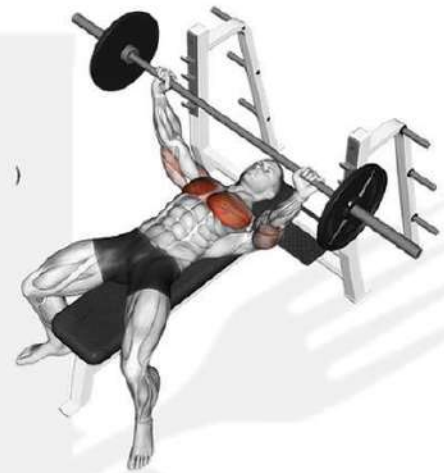

# PECTORALIS MAJOR

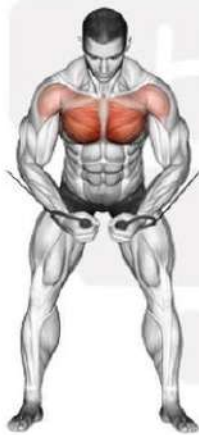## STERNAL (LOWER HEAD)



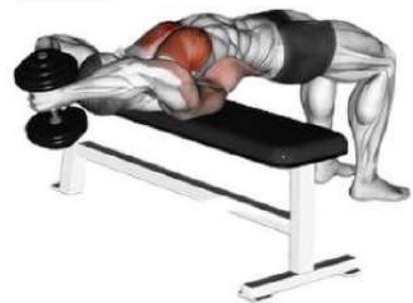Chest Dips



Flat/Decline Bench Press



High Cable Crossover



Lying DB Pullovers

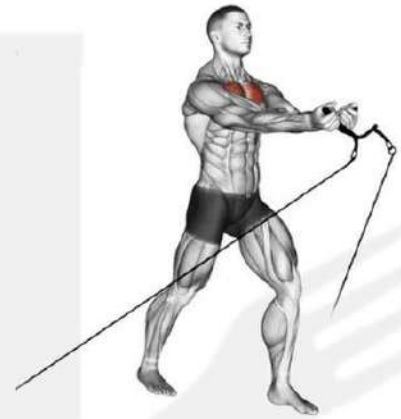

# PECTORALIS MAJOR

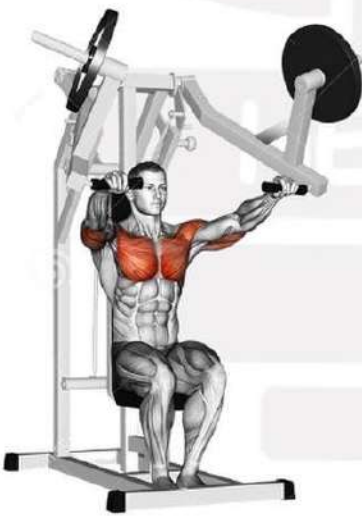## CLAVICULAR (UPPER HEAD)



**Incline Bench Press**



**Low Cable Crossover**



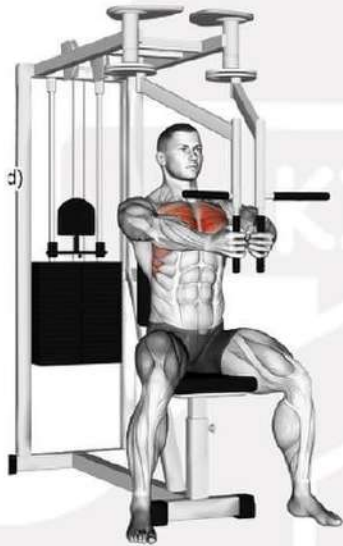**Iso-Lateral Bench  
Press Machine**



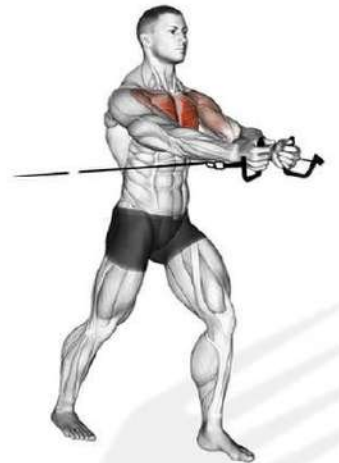**Incline DB Flys**



# PECTORALIS MINOR



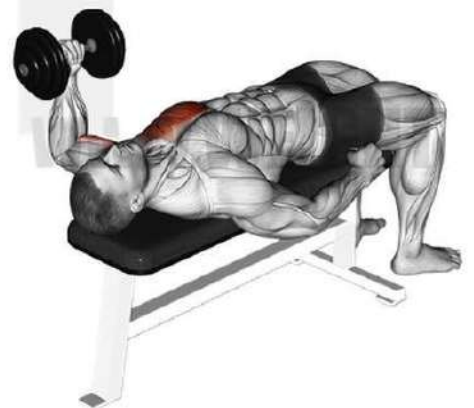**Machine Flys**



**Cable Chest Press**



**Lying/Standing  
Svend Press**



**Single Handed Hammer  
Grip Chest Press**

